



UNIQUE JOURNAL OF AYURVEDIC AND HERBAL MEDICINES

Available online: www.ujconline.net

Review Article

HEMORRHOIDS-(ARSHA): A COMPREHENSIVE REVIEW ON ITS CAUSES AND TREATMENT

Mishra Neha^{1*}, Sharma HP²

¹Lecturer, Shalya Tantra, Pt. K.L.S. Government College Bhopal, MP

²HOD & Reader, Shalya-Tantra, Pt. K.L.S. Government College Bhopal MP

Received 20-09-2013; Revised 18-10-2013; Accepted 17-11-2013

*Corresponding Author: **Dr. Neha Mishra MD Ayu.**

Lecturer, Shalya Tantra, Pt. K.L.S. Government College Bhopal, MP E-mail: drajee_mishra@live.in

ABSTRACT

Hemorrhoids (arsha) are one of the most common ailments of the rectum, affecting as much as half the population by the age of 50. Suffering from hemorrhoids is not only painful but embarrassing as well. Hemorrhoids are swollen, inflamed veins and capillaries around the rectum. They may be classified as either internal or external. Many not only want to know how to heal hemorrhoids but how to heal hemorrhoids fast and naturally. The authors review the role of ayurveda in the management of hemorrhoids (arsha). It has been proved by scientific studies that botanicals improve microcirculation, capillary flow, and to strength the surrounding connective tissues of anus and lower rectum.

Keywords: Hemorrhoids (Arsha), Ayurveda, Causes, Symptoms, Complications, Management.

INTRODUCTION

Hemorrhoids often described as "varicose veins of the anus and rectum", hemorrhoids are enlarged, bulging blood vessels in and about the anus and lower rectum. Hemorrhoids are usually found in three main locations: left lateral, right anterior and right posterior portions. They lie beneath the epithelial lining of the anal canal and consist of direct arteriovenous communications, mainly between the terminal branches of the superior rectal and superior hemorrhoidal arteries, and, to a lesser extent, between branches originating from the inferior and middle hemorrhoidal arteries and the surrounding connective tissue. They are mainly classified as either internal or external as shown in **Figure 1**.

vfjoRizkf.kuks ekaldhyk fo'klfUr ;r~!
v'kkZafl rLeknqP;Urs xqnekxZfujks/kr%!
nks"kkLRO·ekalesnkafIUnw"; fofokkd' rhu~!
ekal·adjkuikuknkS dQoZUR;'kkZafl rk¥txq%!!
va g` fu-7@1(2)

CAUSES

The exact causes of symptomatic hemorrhoids are unknown. A number of factors are believed to play important role including;

1. Irregular bowel habits(constipation or diarrhea)
2. Lack of exercise
3. Nutritional factor(a low-fiber diet)

4. Increased intra-abdominal pressure (prolonged straining, an intra-abdominal mass, or pregnancy),
5. genetics, absence of valves within the hemorrhoidal veins,
6. Aging.
7. Other factors that are believed to increase the risk include
 - Obesity
 - Prolonged sitting
 - Chronic cough
 - Pelvic floor dysfunction.

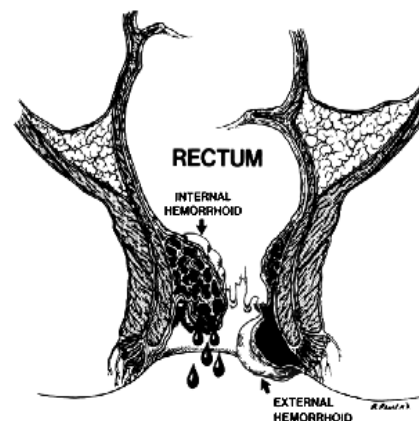


Figure 1: Schematic presentation of types of Hemorrhoids

Evidence for these associations, however, is poor. During pregnancy, pressure from the fetus on the abdomen and hormonal changes cause the hemorrhoidal vessels to enlarge. Delivery also leads to increased intra-abdominal pressures. Surgical treatment is rarely needed in those who are pregnant, as symptoms usually resolve post delivery.

CLASSIFICATION

A) On the basis of position-

1. Internal
2. External
3. Interno-external

B) On the basis of symptoms-

1. Grade I: No Prolapses. Just prominent blood vessels.
2. Grade II: Prolapses upon bearing down but spontaneously reduce.
3. Grade III: Prolapses upon bearing down and require manual reduction.
4. Grade IV: Prolapsed and cannot be manually reduced.

SIGN & SYMPTOMS:

The symptoms of pathological hemorrhoids depend on the type present. Internal hemorrhoids usually present with painless rectal bleeding while external hemorrhoids may produce few symptoms or if thrombosed significant pain and swelling in the area of the anus.

External

If not thrombosed external hemorrhoids may cause little problem.

However when thrombosed they may be very painful with this pain typically resolves over 2 to 3 days. The swelling may take a few weeks to disappear, and after healing a skin tag may remain. If they are large and causing issues with hygiene, they may produce irritation of the surrounding skin and thus causes itching around the anus.

Internal

Internal hemorrhoids usually present with painless, bright red, rectal bleeding during or following a bowel movement. The blood typically covers the stool, a condition known as hematochezia, is on the toilet paper, or drips into the toilet bowl. The stool itself is usually of a normal color. Other symptoms may include mucous discharge, a perianal mass if they prolapse through the anus, itching, and fecal incontinence. Internal hemorrhoids are usually only painful if they become thrombosed or necrotic.

COMPLICATIONS

- Anemia
- Thrombosed strangulated piles

MANAGEMENT

Conservative:

1. Prevention of constipation- Laxative- Triphala churna, Panchasakar churna, Haritaki churna, Abhayaarista.
2. Deepan pachan- Chitrakadi vati , Lavan baskar churna, Agnitundi vati.
3. Arshoghna-Sooranpak, Arshakuthar ras, Shigru guggulu.
4. Hot sitz bath- Tankan bhasma Sphatic bhasma, Triphala kwath Panchawalkal kwath.

5. Rakta stambhak-Bol baddha rasa, Bol parpati, Kukutandatwak bhasma Praval pisthi.
6. Vran ropak-Jatyadi tail, Nirgundi tail.
7. Vednahaar-Madhuyastyadi tail, Triphala guggulu.

Procedures:

1. Kshar sutra ligation:

It is a procedure in which medicated herbal coated thread are applied onto internal and external piles mass within 5-7 days withered piles mass falls off. Cure rate-97%

2. Chedan karma:

A number of surgical excision techniques may be used if conservative management and simple procedures fails. All are associated with some degree of complications including bleeding, infection, anal strictures and urinary retention, due to the close proximity to the rectum to the nerves that supply the bladder. There may also be a small risk of fecal incontinence, particularly of liquid, with rates reported between 0-28 percent.

3. Agni karma:

A number of cauterization methods have been shown to be effective for hemorrhoids, but are usually only used when other methods fail. This procedure can be done using electrocautery, infrared radiation, laser surgery, or cryosurgery. Infrared cauterization may be an option for grade 1 or 2 disease. In those with grade 3 or 4 disease re-occurrence rates are high

4. Ksharkarma:

Involves the applying of a sclerosing agent, such as apamarg kshar snuhi kshar, into the hemorrhoid. This causes the vein walls to collapse and the hemorrhoids to shrivel up. The success rate four years after treatment is ~70%

Benefits of kshar sutra therapy

- Simple safe and sure treatment
- No complications
- No recurrence
- Very economic
- Very high success rate
- No antibiotic required
- Day care surgery
- Useful in all age and cardiac patients

Apathya

Chilies, Fried Foods, Maida product, Non-Veg, Paneer, Constipating foods, Constant sitting, Excessive Pressure in defecation.etc.

Pathya

Cow milk, Butter, Buttermilk, Wheat, Ghee, Rice, Green vegetable, Regular sleep, Exercise, Regular diet, Non suppression of natural urges etc

CONCLUSION

Ayurveda has immense potential to solve many challenging and unresolved problems of the medical world. A hemorrhoid is a common discomfort, that is getting worse by prolonging immediate treatment, which directly affect the economy. *Kshara sutra* ligation takes less time and, if the patient has any

associated systemic disorder, then the procedure can still be performed with proper prophylactic measures. *Kshara sutra* ligation treatment is much more beneficial in comparison with hemorrhoidectomy at maximum point.

REFERENCES

- Johanson JF, Sonnenberg A. The prevalence of hemorrhoids and chronic constipation. An epidemiologic study. *Gastroenterology*. 1990; 99:1856-1857.
- Smith LE. Hemorrhoids. In: Fazio V, editor. *Current Therapy in Colon and Rectal Surgery*. St. Louis, MO: Mosby; 2004; 11-18.
- Aigner F, Gruber H, Conrad F, et al. Revised morphology and hemodynamics of the anorectal vascular plexus: impact on the course of hemorrhoidal disease. *Int J Colorectal Dis*. 2009; 24(1): 105-113.
- Greenspon J, Williams SB, Young HA, Orkin BA. Thrombosed external hemorrhoids: outcome after conservative or surgical management. *Dis Colon Rectum*. 2004; 47(9):1493-1498.
- Bat L, Melzer E, Koler M, Dreznick Z, Shemesh E. Complications of rubber band ligation of symptomatic internal hemorrhoids. *Dis Colon Rectum*. 1993; 36(3):287-290.
- Lee HH, Spencer R J, Beart RW., Jr Multiple hemorrhoidal bandings in a single session. *Dis Colon Rectum*. 1994; 37(1):37-41.
- Pilkington SA, Bateman AC, Wombwell S, Miller R. Anatomical basis for impotence following haemorrhoid sclerotherapy. *Ann R Coll Surg Engl*. 2000; 82(5):303-306.
- Faucheron J L, Gangner Y. Doppler-guided hemorrhoidal artery ligation for the treatment of symptomatic hemorrhoids: early and three-year follow-up results in 100 consecutive patients. *Dis Colon Rectum*. 2008; 51(6): 945-949.
- Person B, Wexner SD. Novel technology and innovations in colorectal surgery: the circular stapler for treatment of hemorrhoids and fibrin glue for treatment of perianal fistulae. *Surg Innov*. 2004; 11(4): 241-252.
- Holzheimer RG. Hemorrhoidectomy: indications and risks. *Eur J Med Res*. 2004;9(1):18-36.
- Bleday R, Pena JP, Rothenberger DA, Goldberg SM, Buls JG. Symptomatic hemorrhoids: current incidence and complications of operative therapy. *Dis Colon Rectum*. 1992; 35(5): 477-481.
- Khan S, Pawlak SE, Eggenberger JC, et al. Surgical treatment of hemorrhoids: prospective, randomized trial comparing closed excisional hemorrhoidectomy and the Harmonic Scalpel technique of excisional hemorrhoidectomy. *Dis Colon Rectum*. 2001; 44(6): 845-849.
- Shastri A. *Sutra Sthana*. 4. Vol. 33. Varanasi: Chaumbika Sanskrit Sansthan; 2001. Sushrutacharya, *Sushruta Samhita*, Ayurved Tatva Sandipika; pp. 126-7.
- Shastri A. *Chikitsa Sthana*. 11th ed. 03. Vol. 6. Varanasi: Published Chaukhamba Sanskrit Sansthan; 1953. Sushrutaacharya, *Sushruta Samhita Dalhanacharya Kaviraj*; p. 35.
- [last accessed on 2009 Dec 10]. Available from: <http://www.haemorrhoids.com>.
- Goligher J, Duthie H, Nixon H. *Surgery of the Anus, Rectum and Colon*. 5th ed. A.I.T.B.S. Publishers and Distributors; 2002; 131-34.
- Shastri A. *Chikitsa Sthana*. 5. Vol. 6. Varanasi: Chaumbika Sanskrit Sansthan; 2001. Sushrutacharya, *Sushruta Samhita*, Ayurved Tatva Sandipika; p. 36.
- Sharma SK, Sharma KR, Singh K. *Kshara Sutra, Therapy in fistula-in-ano and other anorectal disorders*. Rashtriya Ayurved Vidyapeeth (National Academy of Ayurveda): RAV Publication; 1994-95; 48-52.
- Sharma SK, Sharma KR, Singh K. *Kshara Sutra Therapy in fistula-in-ano and other anorectal disorders*. Rashtriya Ayurved Vidyapeeth (National Academy of Ayurveda): RAV-Publication; 1994-95; 161-167.
- Shastri A. *Chikitsa Sthana*. Varanasi: Chaumbika Sanskrit Sansthan; Sushrutacharya, *Sushruta Samhita*, Ayurved Tatva Sandipika, 2001; 36(8): 47.
- Farqurharsons M, Moran B. Farqurharsons, *Text Book of Operative General Gurgery*. 9th ed. Published by International Student; 2005; 439-441.
- Sharma SK, Sharma KR, Singh K. *Kshara Sutra Therapy in fistula-in-ano and other anorectal disorders*. Rashtriya Ayurved Vidyapeeth (National Academy of Ayurveda): RAV Publication; 1995; 44-45.

Source of support: Nil, Conflict of interest: None Declared