



Unique Journal of Medical and Dental Sciences

Available online: www.ujconline.net

Case Report

METAL REINFORCED COMPLETE DENTURE - A CASE REPORT

Arora Sheen J, Arora Aman, Sangwan Ritu*

Room no. 5, DAV© Dental College, Model Town, Yamunanagar, India

Received: 20-10-2015; Revised: 18-11-2015; Accepted: 16-12-2015

*Corresponding Author: Sangwan Ritu

Room no. 5, DAV© Dental College, Model Town, Yamunanagar, India

ABSTRACT

Fracture of the conventional acrylic denture is one of the most common complaints of the patient. This is more evident in patients with heavy masticatory loads and those with parafunctional habits. This calls for the need for better material with good mechanical properties capable of withstanding all the functional loads effectively without fracture. A metal based denture base due to its superior mechanical properties in this respect is a good alternative to acrylic dentures. This article discusses a case report of successful oral rehabilitation of a completely edentulous maxillary and mandibular arch in a patient with the heavy occlusal stresses.

Keywords: Complete Denture, Metal Denture Base, Bruxism, Heavy occlusal stresses.

INTRODUCTION

According to French FA, artificial dentures function like mechanical machines in an anatomic environment. In cases where there is a clash between esthetic and functional requirements, a choice is to be made by favoring one at the expense of the other or make some amount of compromises in most of the situations¹.

The patients with completely edentulous mouth are rehabilitated with heat polymerised acrylic resin complete dentures. But the most common problem seen in these cases is fracture of the denture bases. Denture fracture is usually mechanical or accidental. Mechanical causes are related to faulty design, faulty fabrication and, poor materials choice. Furthermore the fracture of the denture base often occurs by a fatigue mechanism in which relatively small flexural stresses, over a period of time, eventually lead to the formation of a small crack, which propagates through the denture, resulting in fracture. Other factors leading to fracture include heavy masticatory forces, functional or parafunctional forces like those seen in bruxism. Also, when single complete denture is given opposing a natural dentition, fracture rate increases.

The most commonly used material for denture fabrication is acrylic resin. But the mechanical properties of acrylic resin are not capable enough to withstand heavy stresses leading to fracture of the prosthesis². To minimize the possibility of fracture, different methods like use of metal reinforced denture bases³, acrylic resin base reinforced with wire netting, carbon fibre, E glass fibre reinforced PMMA^{4,5}, lucitone 199, Trevalon high, Paladon ultra and visible light polymerized resin⁶ are practiced. Out of all these methods, metal reinforced

dentures were the first to be used as an alternative to conventional acrylic denture base and are still one of the most promising alternatives.


These metallic bases are thin, have superior physical properties, are stronger and have greater resistance to fatigue. Their various other advantages include biocompatibility, high thermal conductivity⁷, no dimensional change through fluids absorption and no interference with phonation⁸. They also reduce burning sensation, allergic reactions, eliminate microbial colonization and hence are more comfortable to the patient.

Besides being used in cases involving heavy stresses, metal based dentures can also be used in variety of clinical situations like single complete denture opposing natural dentition and in patients with neuromuscular disorders like epilepsy.

The purpose of this article is to explain a simple technique of fabricating a complete denture in an edentulous patient with the habit of bruxism.

CASE REPORT

A 55 year old male patient reported to the department of prosthodontics in our college with the chief complaint of repeated fracture of the maxillary and mandibular denture. He had been wearing denture since 7 years and his denture was repaired several times with autopolymerizing acrylic resin. Detailed history revealed that he had the habit of grinding his teeth not only during night but also during day. Denture examination revealed flattened occlusal surfaces. After thorough examination, a metal based complete denture was planned for this patient.



Pre-operative extraoral view

CLINICAL PROCEDURE

1. Preliminary impression for maxillary and mandibular arches was made using impression compound by mucocompressive impression technique. It was poured in Type II Gypsum product.
2. The preliminary casts were obtained and custom trays were fabricated with autopolymerizing acrylic resin. Selective pressure impression technique was used for secondary impression. For this, first border molding was carried out conventionally using low fusing impression compound and then final impression was recorded with zinc-oxide eugenol impression paste. (Fig. 2)
3. Beading and boxing of the impression was done and it was poured in Type III Gypsum. Master cast was obtained and the mould of the same was made with reversible hydrocolloid (agar agar) impression material. A refractory cast was poured with ethyl silica bonded investment material.

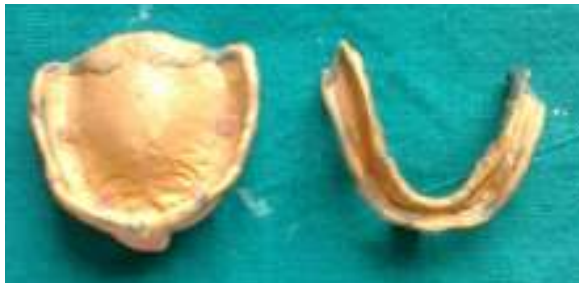

Figure 2: ZOE impression of maxillary and mandibular arch

4. On the refractory cast, denture base pattern wax was adapted and then investing and casting procedures were carried out. Metal framework was finished and polished with electrolytic polishing in an electrolytic polishing device.
5. The metal framework so obtained was tried in patient's mouth and was checked for stability and extensions up to the junction of soft and hard palate in the maxillary arch whereas in the mandibular arch, the framework ended just before the retromolar pad area.

6. The temporary denture bases were fabricated on the master cast and then occlusal rims were fabricated on these denture bases. Maxillo-mandibular relations were recorded and evaluated properly for aesthetics and phonetics.
7. Articulation was done followed by teeth arrangement. And try in was done in patient's mouth.
8. After trial, the regular protocol of flasking and dewaxing procedure was carried out. Before packing, the metal framework was placed on their respective maxillary and mandibular cast and the acrylization procedure was completed.
9. The prosthesis was then finished, polished and delivered.

DISCUSSION

Completed denture made in conventional manner proves to be satisfactory in most of the patients, but in compromised patients, conventional methods have certain disadvantages. Polymethyl methacrylate denture bases have good mechanical, biological and aesthetic properties, their impact and fatigue strength however is not satisfactory in clinical situations that include heavy masticatory forces like those seen in bruxism and clenching.

There are several methods to increase the resistance of denture base to mechanical stress. Acrylic resin base reinforced with several types of fibres like carbon, aramide, woven polyethylene and glass fibres^{9,10} have been introduced in past, but these all have certain disadvantages. Carbon and aramid fibres strengthen PMMA but cause clinical problems like difficulty in polishing. Woven polyethylene fibres cause difficulty in processing as it require etching, preparing and positioning layers of woven fibres which is impractical for dental office. With glass fibres, there is difficulty in achieving adequate impregnation of the fibres with PMMA. Reinforcement by incorporating butadiene styrene rubber has also been used (Rubber toughening). A metal reinforced denture base is usually preferred among all the reinforcement methods as it reduces the likelihood of denture fracture caused by extensive biting and impact force problems and do not cause much difficulty in processing.

Variety of metals can be used to fabricate the prosthesis including cobalt -chromium, nickel-chromium and titanium. These metal bases offer several advantages including high rigidity, fracture resistance, excellent strength to volume ratio, good adaptation to the supporting tissues, high thermal conductivity and no dimensional change in time.

Metal denture bases have certain disadvantages including high cost, difficult refitting of the denture and increased time consumption in comparison to the acrylic resins. However, the advantages seem to outweigh the disadvantages. Metal denture bases help significantly in solving patient's long term problem of frequent denture fracture.

CONCLUSION

This article concludes that the metal denture base can be used successfully in patients with the heavy occlusal stresses and bruxism. Metal denture base decreases the amount of bone

resorption, increases stability, retention, provides a close adaption to the underlying tissue, eliminates the acrylic denture-induced allergic reactions, avoids microbial colonization and decreases the fungal growth that usually occurs under acrylic denture bases.

REFERENCES

1. Prasad A, Prasad K, Hegde C. Management of completely edentulous maxillary arch opposing natural dentition – A case report. *NitteUniv J Health Sci* Sept 2012; 2(3): 39-41.
2. Shimizu H, Tsue F, Obukuro M, Kido H, Takahashi Y, Ohmura H. Fracture strength of metal based complete maxillary dentures with a newly designed metal framework. *Int Chin J Dent* 2005; 5: 35-38.
3. Jameson W S. Fabrication and use of a metal reinforcing frame in a fracture prone mandibular complete denture. *J Prosthet Dent* 2000; 83: 476-479.
4. Katja K Narva, Vallittu PK, Helenius H, Yli-Urpo A. Clinical survey of Acrylic Resin Removable Denture Repairs with Glass fiber reinforcement. *I JProsthodont*, 2001; 14: 3.
5. Vallittu P K. Glass fiber reinforcement in repaired acrylic resin removable dentures: Preliminary results of a clinical study. *Quint Int* 1997; 28: 39-44.
6. Stipho H D. Repair of acrylic resin denture base reinforced glass fiber. *J Prosthet Dent* 1998; 80: 546-550.
7. Chopra D, Gupta V, Sethi P. Maxillary Complete Denture with Metal Palate Base: A Case Report. *J Dent Sci Oral Rehab* Jan- Mar 2013; 44-46.
8. Postic SD. Design of Complete Denture Reinforced with Metal Base. *Serbian Dent J* 2013; 60(1): 15-20.
9. Chen SY, Liang WM, Yen PS. Reinforcement of acrylic denture base resin by incorporation of various fibers. *J Biomed Mater Res*. 2001; 58(2): 203-8.
10. Alla RK, Sajjan S, Alluri VR, Ginjupalli K, Upadhy N. Influence of Fiber Reinforcement on the Properties of Denture Base Resins. *JBiomat Nanobiotech*, 2013; 4: 91-97.

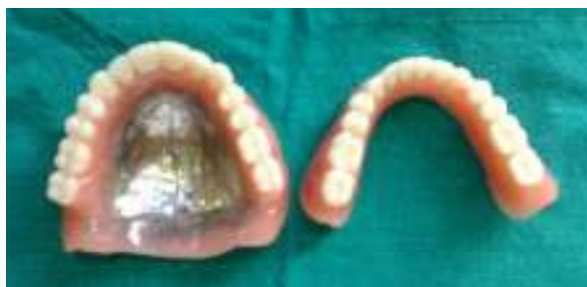

Figure 3: Final metal prosthesis

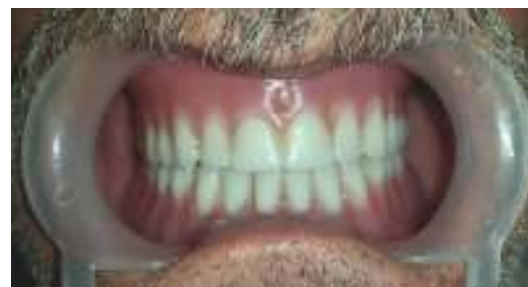

Figure 4: Intraoral view



Figure 5: Extraoral view

Source of support: Nil, Conflict of interest: None Declared